

Studying the Morphological Variation of the Septions of the Maxillary Sinus

Opolovnikova Kristina Sergeevna¹

Abstract: This article includes the results of a scientific study, the purpose of which is to identify the prevalence and morphological characteristics of sinus septa in the maxillary sinuses among residents of the Bukhara region using cone-beam computed tomography, and to determine their relationship with gender, age and dental status. Based on the obtained data, it should be noted that the cone-beam computed tomography of the maxillary sinus was a powerful tool for identifying septa of different height, type, localization, not depending on the gender or age of the patient, but differences were found depending on the type of adentia.

Key words: maxillary sinus, sinus septa, sinus lift, sinus floor enlargement, cone beam computed tomography.

In recent years, otorhinolaryngologists are more likely to meet with endoscopic sinus surgery, and in dentistry with sinus lift surgery, in the posterior region of the maxillary region, which requires a detailed knowledge of the anatomy of the maxillary sinus and possible anatomical variations. Detailed knowledge of the morphological anatomy of the maxillary sinus allows accurate planning of preoperative treatment, which will correspond to the avoidance of complications, lead to an increase in surgical problems, time and postoperative complications [2,3,9,12].

The maxillary sinus is an approximately pyramidal cavity in the facial region of the skull, the base of which is adjacent to the nasal cavity, and the blunt apex is directed towards the zygomatic bone. It has several sinus recesses: an alveolar recess directed downwards, a zygomatic recess directed laterally, a variable palatal recess (a continuation of the alveolar recess) between the floor of the nasal cavity and the roof of the oral cavity, and an infraorbital recess directed upwards. Bounded by the orbital surface of the maxilla. There are six walls of the maxillary sinus: the upper, anterior, lateral and medial walls are wide, the posterior and lower walls are narrow. [23] In the cavity of the sinus, partitions are often found, which are the walls of the cortical bone dividing the sinus into smaller compartments. These septa are called maxillary, sinus, antral, or Underwood's septa. The main function of the septa is to act as a support for masticatory force during the dentate phase of life. [21]

Sinus septa were first described by Underwood [18] in 1910 as walls of cortical bone within the sinus, and the shape resembled an inverted Gothic arch emerging from the inferior or lateral walls of the sinus. The etiology of antral septa has been put forward by several hypotheses [8, 19,] some of them are septa that arise as a result of the development of the upper jaw itself are called primary septa, septa arising from uneven pneumatization of the sinus floor after tooth loss are called secondary septa. [7] The conducted studies were mainly aimed at identifying the septa of the maxillary sinuses in the edentulous jaws [8,14]. In general, the prevalence of septa in the works devoted to the maxillary sinuses ranges from 16-48% [2,3,4, 13,14,20,]. For example, prevalence was 27% in a study from Korea, 44% in a study in Brazil, and 69% in a study in South Africa, 46% in Saudi Arabia, 30% in Taiwan.

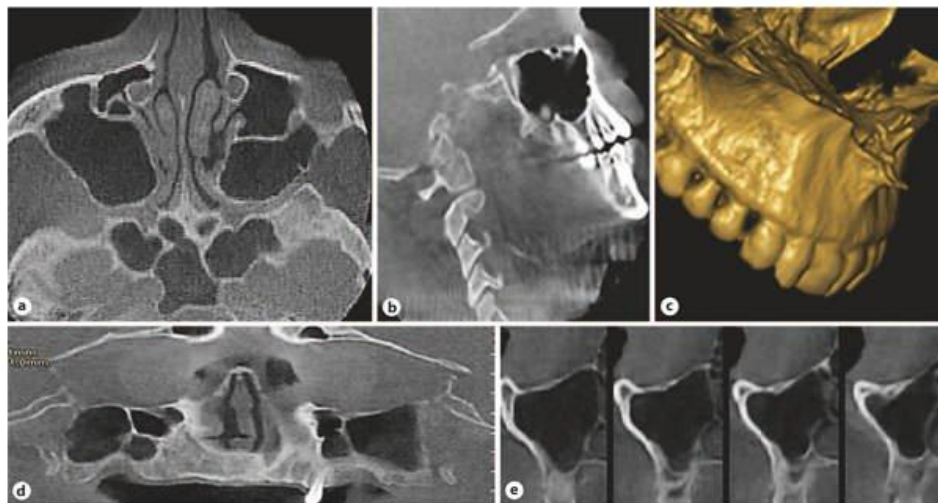
Sinus septa have various anatomical variations and are classified according to parameters such as septa location, morphology, and orientation [20]. If we evaluate their location, the partitions located between the area of the first and second premolars (the front wall of the sinus) and the mesial part of the first molar. Septa of the middle region exist between the mesial part of the first molar and the distal part of the second molar. The partitions located between the distal part of the second molar and the posterior wall of the sinus are posterior. From a morphological point of view, completed (complete) or incomplete (partial) partitions can be distinguished. The septa are also classified according to the orientation of the septa, the transverse septa extending in the mediolateral direction and the sagittal septa in the anteroposterior direction [4,5,6,10,12,15,17]. Evaluation of the anatomical structures characteristic of the maxillary sinus plays an important role in the success of sinus surgery. Therefore, an accurate and definitive radiological assessment is necessary. More commonly, dental panoramic radiography (OPTG), computed tomography (CT), or cone beam computed tomography (CBCT) are used to detect sinus septa [12]. CBCT provides high resolution 3D imaging at a relatively low effective dose and overcomes the limitations of traditional 2D techniques, especially with regard to overlay and magnification. Therefore, subtle structural differences can be identified and evaluated more accurately. When comparing the prevalence of septa in CBCT versus conventional radiographic techniques, some studies have observed inaccurate results on panoramic radiographs, with up to 50% false negatives found. Therefore, it is reasonable to use CBCT when evaluating the maxillary sinuses [1]. It should be noted that in our region such work, especially at the stage of mixed dentition, has not been carried out.

¹ Assistant of Department of Anatomy, clinical anatomy (OSTA) of Bukhara State Medical Institute named after Abu Ali ibn Sino

The aim of the study was to analyze and compare the incidence, height, and morphology of maxillary sinus septa in adults with serrated, partial, and edentulous teeth, as well as children and adolescents with mixed dentition using CBCT.

Materials and methods. This study retrospectively assessed CBCT images of 485 people (225 women, 180 men, 80 children) who presented to a private imaging center within 1.5 years. Selected images were obtained in adults for reasons of trauma, sinusitis, pre-operative image for deviated septum, as well as to assess the implant site and surgery on an impacted third molar. In children, CBCT was performed for trauma, sinusitis, and to evaluate impacted teeth and various cystic masses, as well as previous surgery to remove the adenoids. The age range of the adult population was from 17 to 74 years, and children - from 6 to 10 years. Each right and left maxillary sinus was identified as a segment.

All CBCT scans were acquired using the next generation i-CAT Cone Beam Computed Tomography (Imaging Sciences International, LLC, Hatfield, PA, USA). All CBCT scans were acquired using the next generation i-CAT Cone Beam Computed Tomography (Imaging Sciences International, LLC, Hatfield, PA, USA). Morphology, localization, and extent of the maxillary sinus septum were assessed on axial, sagittal, transverse, and reconstructed panoramic images, using three-dimensional reconstructions if necessary (Pic. 1). In order to avoid errors in the localization of the partitions, the technique of multiplanar reconstruction was used. Each septated maxillary sinus was divided into three parts: anterior = mesio-distal side of the second premolar; median = distal second premolar to distal second molar and posterior = distal second molar. All examinations and measurements were performed by a maxillofacial radiologist (KO). Reconstructed 1 mm panoramic images were used to determine the course and measure the exact height of the sinus septa. The height of the septa was measured in three areas along the course of the septa through the sinus floor: lateral, medial, and medial sides, based on previous studies [12,14]. The average of these measurements was set as the final measurement. At the same time, the angle between the direction of the septum and the median palatal suture was also measured using axial images. All measurements were performed with software programmed for an automated image measurement tool. All measurements were carried out 3 times by the same observer (CO). The same observer also performed the study twice, 2 weeks apart, to detect intraobserver variability. Statistical analysis was performed using SPSS software version 12.0.1 (SPSS, Chicago, IL, USA). To evaluate intra-observer reliability, the Wilcoxon signed rank test for matched pairs was used for repeated observer measurements. Independent groups in the study were compared using the Mann-Whitney U-test; results were expressed as mean \pm standard deviation. Non-parametric data were compared using the Kruskal-Wallis test. The Pearson χ^2 test was performed for statistical analysis among gender, age, location, and measurements ($p < 0.05$).



Pic. 1. Reconstructed axial (a), sagittal (b), 3D (c), panoramic (d), and transverse (e) CBCT images.

Results and discussions.

The prevalence of sinus segments with septa was 76% (369/485) in 248 adult patients (52% in men and 48% in women) in children (15%). A total of 369 septa were found in 228 patients. One hundred and sixty-six (44.9%) septa were identified on the right side, while 203 (55%) were on the left. In total, there were 13 (3.2%) septa completely edentulous (CE), 198 (53.9%) septa edentulous, and 14 (3.8%) septa mixed occlusion of the maxillary segments. Primary septa were found in 85 (23.3%) edentulous (PE) segments as well as 59 (16.2%) secondary septa in patients with PE. Septa were detected unilaterally in 148 segments (40. Intra-observer agreement was estimated at 96.9% between the two measurements; therefore, there was no statistically significant difference between the two intra-observer measurements ($p > 0.05$).

Unilateral septa were most common (12 cases; 3.25%) in cases with mixed dentition, in patients with bilateral occlusion, septa were most often detected (85; 23%). Unilaterally 2 septa were detected in 4 (1.08%) cases of CE, bilaterally 1 septum in 4 (1.08%) cases, bilaterally 2 septa on one side and 1 septum on the other side in 1 case (0.2%), unilaterally 3 septa in 2 people (0.4%) and bilaterally 3 septa in 2 CE cases (0.4%).

In cases of PE, septa were identified with the following distribution: unilaterally 1 septum was detected in 54 out of 187 (28.8 %), unilaterally 2 septa in 5 (2.6 %), bilaterally 1 septum in 45 (24 %) persons, bilaterally 2 septa in 2 (1%) cases,

bilaterally 2 septa on one side and 1 septum on the other side in 26 people (13.9%), unilaterally 3 septa in 2 people (2%), bilaterally 3 septa on one side and 1 septum on the other hand, in 5 people (2.6%), bilaterally 3 septa on one side and 2 septa on the other side in 2 patients (1%) (Table 1).

Analysis of the anatomical location of the septa within the sinus showed that 45 (12.2%) septa were located in the anterior section, 254 (69.1%) in the middle section, and 70 (18.6%) in the posterior section. The location of the septa observed in all study groups showed a greater prevalence (69.1%) in the middle section than in the anterior and posterior sections (Table 2).

Table 1. Distribution of septa in segments of the maxillary sinus

(Results are expressed as numbers with percentages in parentheses)

Maxillary septum type	Septa	Patients with septa	Segments with septa	Edentate with septa	PE – primary with septa	PE – other with septa	CE with septa	Mixed dentition with septa
1 septum on one side	123 (33,3)	123	123	59	27	27	0	10
2 septa on one side	22 (5,69)	11	11	11	3	2	4	2
Bilaterally 1 septum on either side	136 (36,9)	68	136	85	26	19	4	2
Bilaterally 2 septa on either side	12 (3,2)	3	6	10	1	1	0	0
2 septa on one side and 1 septum on the other side	51 (14,1)	17	34	24	20	6	1	0
3 septa on one side	3 (0,8)	1	1	1	1	1	0	0
3 septa on one side and 1 septum on the other side	12 (3,8)	3	3	3	5	2	2	0
3 septa on one side and 2 septa on the other side	10 (2,2)	2	2	6	1	1	2	0
Total	369	228	316	198 (53,9)	85 (23,03)	59 (16,2)	13 (3,2)	14 (3,8)

The height measurements of each individual baffle varied in different regions. Comparison of mean values of septum measurements of PE and CE areas showed statistically significantly higher values at all measurement points ($p < 0.05$) than in other areas. The division of septa found in PE areas into those located apically to the remaining teeth (primary septa) and located in close proximity to areas without teeth (other septa) showed no statistically significant difference between the height of septa in groups ($p > 0.05$). On the other hand, primary septa in PE showed statistically higher values compared to CE regions (Table 2).

Table 2. Location of the septum, measurement of height depending on the dental status.

Dental status	Septum location, n				Mean septum height \pm SD, mm		
	anterior	middle	posterior	total	lateral	middle	medial
Edentate	19	152	27	198 (53,9)	4,15 \pm 2,08	4,85 \pm 2,38	5,99 \pm 2,92
PE – primary	10	49	26	85 (23,03)	3,18 \pm 3,39	4,88 \pm 3,18	6,54 \pm 3,27
PE – other	10	40	9	59 (16,2)	4,54 \pm 3,87	6,22 \pm 3,92	7,09 \pm 4,11
CE	3	7	3	13 (3,2)	4,70 \pm 1,82	5,33 \pm 2,64	6,88 \pm 3,42
Mixed dentition (children)	3	6	5	14 (3,8)	4,12 \pm 2,88	4,32 \pm 2,90	4,55 \pm 2,88
Total	45 (12,2)	254 (69,1)	70 (18,6)	369 (100)	3,73 \pm 0,76	5,12 \pm 0,88	6,21 \pm 1,01

The average height of the septa in men was 4.86 ± 2.01 mm, in women - 5.02 ± 2.14 mm, and the average height in children and adults was 4.33 ± 1.92 and 5.5 ± 2.64 mm respectively. The range of septa in the study group was 1–10.3 mm in men and 2–15 mm in women. There were no statistically significant differences between the heights of the maxillary sinus septa depending on gender or age ($p > 0.05$). At the same time, the angle of the septum in the anterior part of the maxillary sinus ranged from 34.1 to 90.6° with an average value of $62.2 \pm 15.05^\circ$, the angle of the septum in the middle region ranged from 44.8 to 118° with an average value of $75.8 \pm 18.6^\circ$, and the angle of the septum in the posterior region of the maxillary sinus ranged from 58.1 to 123.6° , on average $90.75 \pm 19.4^\circ$ (Table 2). Significant differences in septal angle were noted between the anterior region of the maxillary sinus and the posterior region ($p < 0.05$). All septa found had a mediolateral orientation.

The prevalence of septa of 60% in this study was higher than the 16–33% reported in previous studies [1,9,10,12,15,16,17]. This difference may be due to the difference in x-ray studies. The higher prevalence in our study was based on the thin slice interval of CBCT images (0.3 mm). With regard to the location of the septa, a greater frequency of occurrence was found in the middle sections, while in several studies [7,12,15,17,20,]. However, the morphology of the septa showed considerable

variability. This can be seen from the results obtained by measuring each septum in 3 aspects along its medial-lateral dimension. These differences may be related to the comparison of edentulous septa with PE septa [2,10,12,14,18]. However, our results contradicted these data as the mean septal height in CE cases was higher than both types of septa in PE cases, but similar to the results obtained by Koymen et al. [25].

Previous studies have reported varying septal heights of 5.6 to 20.6 mm [5,7, 9, 13, 24, 25,26] in other populations. However, the mean septal height in adults in our study was lower than in some other populations [4,6,7,13,24]. A likely reason for the difference is that Neugebauer et al. [24] did not distinguish between children and adults in their study, while Naitoh et al. [25] examined only dry skulls of children.

There is a limited number of studies investigating children's partitions [24,25] that have been published. With the advent of endoscopic sinus surgery in adults, studies have begun to evaluate its safety and efficacy in children. Accurate knowledge of the morphology of the maxillary sinus septum in children is important and allows accurate planning of endoscopic sinus surgery and helps to avoid complications. It should be noted that maxillary septa also exist in children. The height of these maxillary septa was similar to that of adult patients with no significant difference in this study. The prevalence of septations does not depend on the gender or age of the patient, but there are differences depending on the type of adenitis. Differences between results from different studies may reflect differences between measurement methods, tools used to collect data, and differences between study populations.

Conclusions: Approximately 60% of patients had at least 1 septum, this is not a contraindication to surgery, but only indicates the need for CBCT of the maxillary sinus to assess sinus morphology and identify sinus septa to prevent complications. Sinus septa were almost equally common in both males and females, equally common in patients with dentate and edentulous posterior maxillae, and septa were also found in children.

Literature:

1. Al-Zahrani MS, Al-Ahmari MM, Al-Zahrani AA, Al-Mutairi KD, Zawawi KH. Prevalence and morphological variations of maxillary sinus septa in different age groups: a CBCT analysis. *Ann Saudi Med.* 2020 May-Jun;40(3):200-206.
2. Güncü GN, Yildirim YD, Wang HL, Tözüm TF. Location of posterior superior alveolar artery and evaluation of maxillary sinus anatomy with computerized tomography: A clinical study. *Clin Oral Implants Res* 2011; 22(10): 1164-7.
3. Hadchiti W, Nasseh I, Hayek E, Mora F, Bouchard P. Prevalence, location and orientation of maxillary sinus septa. *Ann Oral Maxillofac Surg.* 2014;2:9.
4. Irinakis T, Dabuleanu V, Aldahlawi S. Complications during maxillary sinus augmentation associated with interfering septa: a new classification of septa. *Open Dent J.* 2017;11:140–150.
5. Jang S Y, Chung K, Jung S, Park H J, Oh H K, Kook M S. Comparative study of the sinus septa between dentulous and edentulous patients by cone beam computed tomography. *Implant Dent.* 2014;23(04):477–481.
6. Kocak N, Alpoz E, Boyacioglu H. Morphological Assessment of Maxillary Sinus Septa Variations with Cone-Beam Computed Tomography in a Turkish Population. *Eur J Dent.* 2019 Feb;13(1):42-46.
7. Neugebauer J, Ritter L, Mischkowski RA, Dreiseidler T, Scherer P, Ketterle M, Rothamel D, Zöller JE: Evaluation of maxillary sinus anatomy by cone-beam CT prior to sinus floor elevation. *Int J Oral Maxillofac Implants* 2010;25:258–265
8. Orhan K, Kusakci Seker B, Aksoy S, Bayindir H, Berberoğlu A, Seker E. Cone beam CT evaluation of maxillary sinus septa prevalence, height, location and morphology in children and an adult population. *Med Princ Pract.* 2013;22(01):47–53.
9. Rosano G, Taschieri S, Gaudy JF, Lesmes D, Del Fabbro M. Maxillary sinus septa: A cadaveric study. *J Oral Maxillofac Surg* 2010; 68(6): 1360-4.
10. Schriber M, von Arx T, Sendi P, Jacobs R, Suter VG, Bornstein MM. Evaluating Maxillary Sinus Septa Using Cone Beam Computed Tomography: Is There a Difference in Frequency and Type Between the Dentate and Edentulous Posterior Maxilla? *Int J Oral Maxillofac Implants.* 2017 Nov/Dec;32(6):1324-1332.
11. Shen EC, Fu E, Chiu TJ, Chang V, Chiang CY, Tu HP. Prevalence and location of maxillary sinus septa in the Taiwanese population and relationship to the absence of molars. *Clin Oral Implants Res.* 2012 Jun;23(6):741-745.
12. Toprak ME, Ataç MS. Maxillary sinus septa and anatomical correlation with the dentition type of sinus region: a cone beam computed tomographic study. *Br J Oral Maxillofac Surg.* 2021 May;59(4):419-424.
13. Wen SC, Chan HL, Wang HL. Classification and management of antral septa for maxillary sinus augmentation. *Int J Periodontics Restorative Dent* 2013; 33(4): 509-17.

14. K.S. Opolovnikova STUDYING THE MORPHOLOGICAL VARIATION OF THE MAXILLARY SINUS PARTITIONS IN RESIDENTS OF THE BUKHARA REGION WITH THE HELP OF CONE-BEAM COMPUTED TOMOGRAPHY //New Day in Medicine 5(43)2022 91-97
15. Ополовникова К. С. Возрастное Развитие Верхнечелюстной Пазухи В Постнатальном Онтогенезе (Обзор Литературы) //CENTRAL ASIAN JOURNAL OF MEDICAL AND NATURAL SCIENCES. – 2022. – Т. 3. – №. 1. – С. 143-149.
16. Кристина Ополовникова, Елена Харибова Сравнительная возрастная характеристика околоносовых пазух в постнатальном онтогенезе (обзор литературы) // ОИИ. 2021. №6/S. URL: <https://cyberleninka.ru/article/n/sravnitel'naya-vozzrastnaya-harakteristika-okolonosovyh-pazuh-v-postnatalnom-ontogeneze-obzor-literatury>(дата обращения: 15.04.2022).
17. Алимова, Н. П. (2022). Анализ Антропометрических Параметров Лицевой Области И Физического Развития Детей С Гипертрофией Аденоидов До И После Аденоэктомии. CENTRAL ASIAN JOURNAL OF MEDICAL AND NATURAL SCIENCES, 3(3), 132-137.
18. Баймурадов Р.Р. ПОКАЗАТЕЛИ КРОВЕННЫХ СОСУДОВ СЕМЕННИКОВ БЕЗБРОДНЫХ КРЫС //Всемирный научно-исследовательский журнал. – 2022. – Т. 3. – №. 1. – С. 3-10.
19. Muzafarova, K. S., Radjabovich, B. R., & Joraboy, S. (2022). Morphometric Parameters of the Trunk in Children with Scoliosis. CENTRAL ASIAN JOURNAL OF MEDICAL AND NATURAL SCIENCES, 3(3), 144-147
20. Малика Мухиддиновна, И. (2022). ВЛИЯНИЕ ХРОНИЧЕСКОГО ПОТРЕБЛЕНИЯ ЭНЕРГЕТИКОВ НА ПЕЧЕНЬ И ПОЧКИ ЭКСПЕРИМЕНТАЛЬНЫХ КРЫС. Международный журнал философских исследований и социальных наук , 2 (4), 6–11.